



Slide Seminar

“Practical Approach to Placental Pathology”

IAP-ID Invited Foreign Guest Speaker

Dr. Jane Dahlstrom, OAM

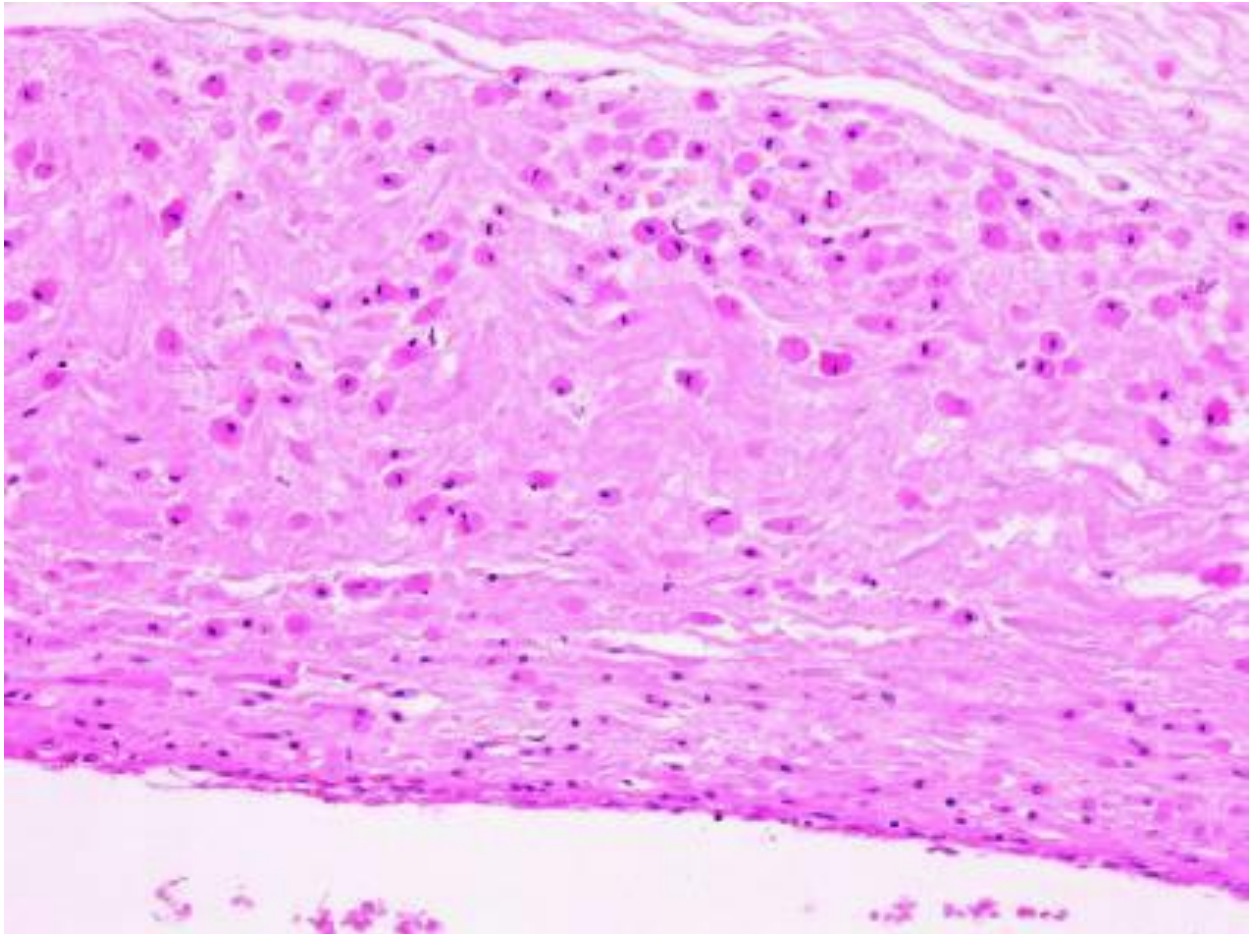
- Chair and Professor of Pathology,
College of Health and Medicine,
Australian National University
Canberra, Australia
- Executive Director, ACT Pathology
Canberra Health Services, ACT Government
- Senior Staff Specialist, Anatomical Pathology, ACT
Pathology
- Chairperson, Education Committee of International Academy
of Pathology

Case Histories

Case 1

Female 38 years. 41 + 3/40 Baby hypoxic. Now seizures, multi-organ failure. Placental disc weight 600 grams.

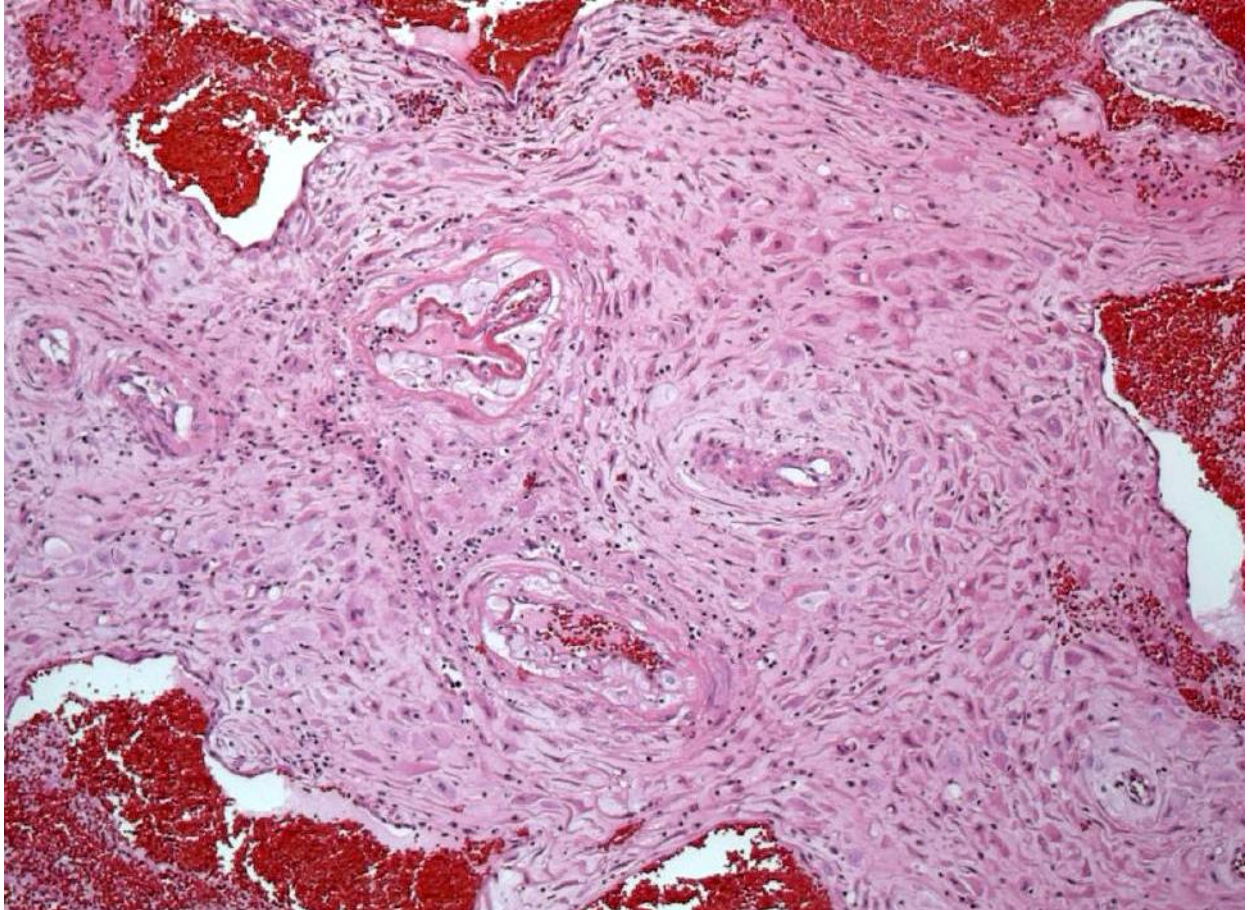Photomicrograph from wall of one umbilical artery



Case 2:

Female 31 years. 34/40 with pre-eclampsia. Placental disc weight 265 grams.

Photomicrograph of decidua

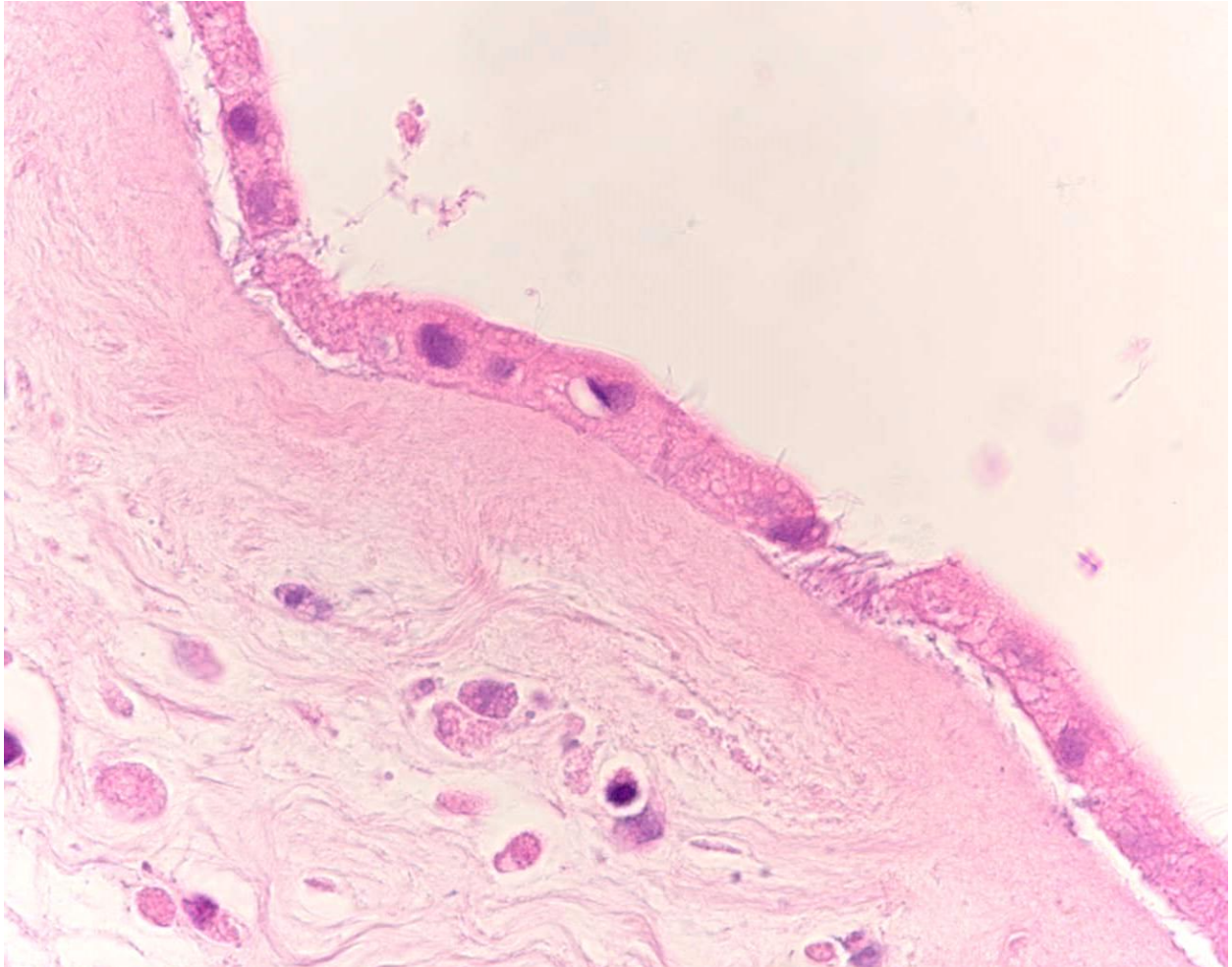


Case 3:

Female 43 years. 29+3/40. Well pregnancy.

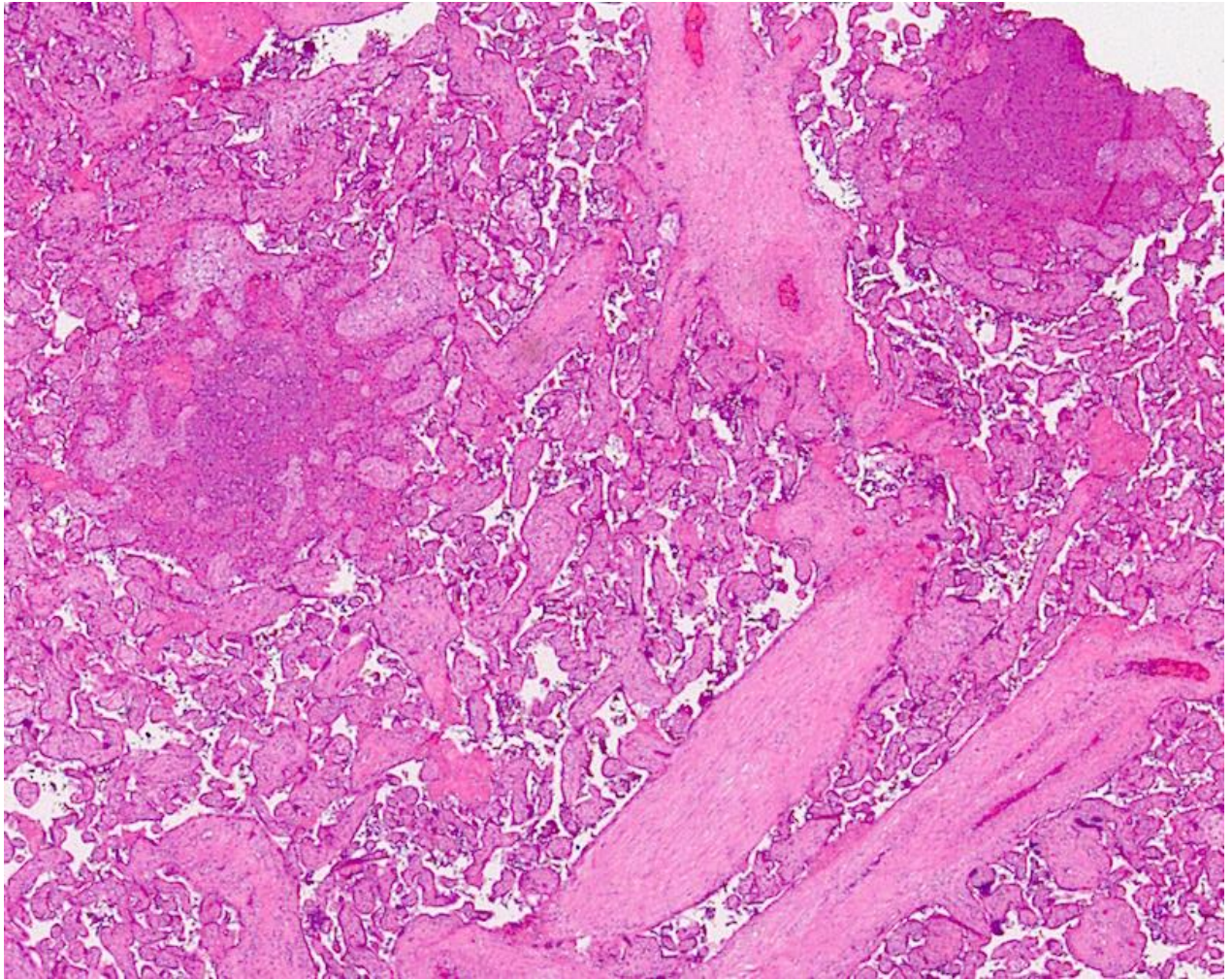
?chorioamnionitis. Placental disc weighed 430 grams.

Photomicrograph of extraplacental membranes



Case 4:

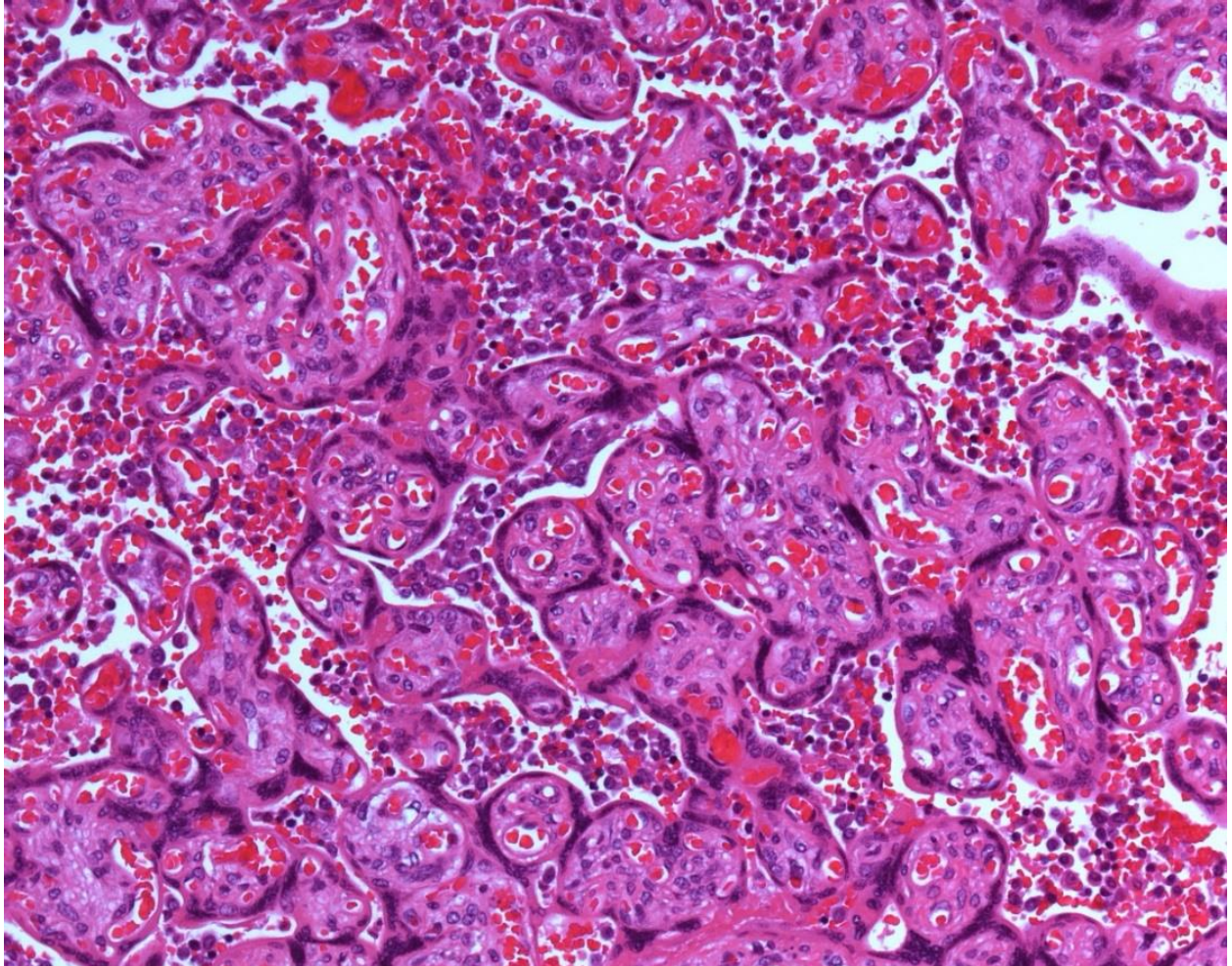
Female 33 years. FDIU at 30/40. ? IUGR (1295 grams).
Febrile on admission. Placental disc weighed 241 grams.
Photomicrograph of placental disc



Case 5:

Female 26 years. G2P0. Raised ALKP in 1000's. Placental disc weighed 380 grams.

Photomicrograph of placental disc



Case 6:

Female 32 years. 31+4/40. IUGR (800 grams). Placental disc weighed 263 grams.

Photomicrograph of placental disc

